

Dentistry Clinical

The art of the perfect smile

Rahul Doshi discusses the importance of creating aesthetic and functional transitional restorations

The purpose of this article is to outline a simple system to achieve a functional occlusion and a predictable aesthetic rehabilitation with porcelain veneer techniques. It follows the fundamentals of smile design, tooth morphology, form and function. Creating beautiful temporaries is one of the best ways of having satisfied patients who will grow your practice by referring more people.

The team approach

The combination of knowledge and artistic skills of the dentist and the close interaction with the ceramist technician provides a predictable end result. The dentist's role is to understand the needs of the patient and formulate a plan that includes not only aesthetic considerations, but occlusal, periodontal and functional requirements.



Before and after photograph of the patient with her new smile

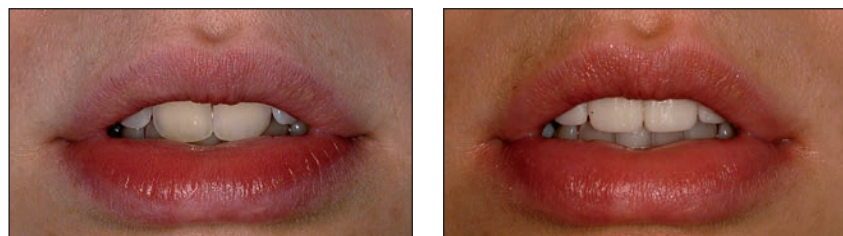
The principles of smile design

In developing anterior restorations, specifically veneers and crowns, the dentist must determine the following important factors:

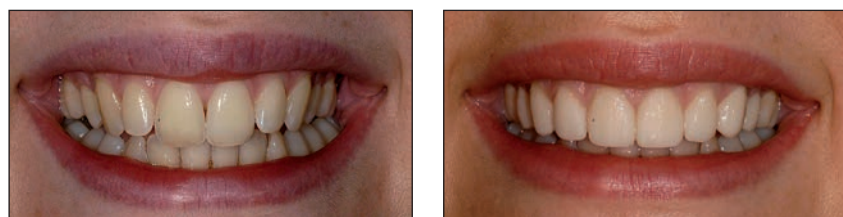
- The position of the incisal edge in the 'rest position' of the lips. This is determined by the age of the patient and whether they are male or female
- The width/length ratio of the central incisors should be 75-80%
- The colour of the required restorations and the colour of the existing dentition/restorations; thus determining the thickness of the restoration, necessary tooth reduction and the choice of feldspathic or pressed porcelains
- The size of teeth using The Golden Proportion rule: an anterior photograph (a two-dimensional image) should produce the width ratio between central incisor: lateral incisor: canine of 1.6: 1: 0.6
- The size and position of the centre line should be vertical, not canted, and ideally in the midline
- The arch-form needs to be assessed for lingual or labial version of the teeth in comparison to the ideal curved arch-form
- The position of contact points and the position of the incisal embrasure areas progressively graduate cervically from the anterior to the posterior teeth
- The size of embrasure areas progressively increase from the anterior to the posterior
- The axial alignment of teeth should converge to the midline at an angle of 5°.

Case one

This highlights the importance of understanding the correct amount of tooth visible with 'lips at rest' when determining the new incisal edge position for designing the perfect smile.



The change in the visible amount of tooth, of the central incisors, with 'lips at rest' determine the new incisal edge position



Before and after smile with change in height of the teeth of the central incisors

It's Evident!



Send



Attach



Copy



Paste

From: **Stephen Selwyn**
To: **All Dentists**
Subject: **Ray Bertolotti**

Hi Everyone

Last week at the BDA conference there was a marvellous lecture by world famous Professor Ray Bertolotti.

Raymond Bertolotti is perhaps best known for introducing "total etch" to North America in 1984. He has been credited as the guru who, in 1985, coined the phrase "adhesion dentistry".

Ray also introduced Caries Detector in 1984 and self-etching primers in 1992. The sectional Contact Matrix system, "Microprime B", Accolade PV, "Microetcher" sandblasting, cantilevered adhesion bridges and intraoral tin-plating are also his innovations. He has published extensively in journals, as well as authoring four dental textbook chapters. He is a Fellow of the American Academy of Dental Materials, a Fellow of the American College of Dentists, a Fellow of the Pierre Fauchard Academy, and an Accredited member of the Academy of Cosmetic Dentistry.

In his first lecture he strongly recommended the use of a Microetcher to mechanically prepare the tooth surface for enhanced bonding. He stated that he would 'throw away his handpiece' if he did not have one. Using 50 micron aluminium powder in a very reliable device, he described many uses for it.

His second lecture was all about bonding. He explained the various methods of bonding and came down strongly in favour of 2 step self-etch materials. They usually took no more time than other methods and had better results. While there were a number of these, he required certain criteria which included ease and speed of use, high retention, a dual-cure ability and very importantly, especially when cementing inlays, an ultra thin film thickness. Certain bonds had a thickness that could prevent the inlay from seating properly during cementation. The bonding agent that fulfils all these criteria is Prelude which can be used for both etch and rinse and self-etch techniques and has the ability to be self-cured with a short application of Link. Post treatment sensitivity is eliminated and adhesion is as good or exceeds other bonding agents. With each step taking only 10 seconds it is quick and easy to use and very economical.

Available directly from Evident, Prelude is the perfect choice for all your bonding needs.

To order Prelude, FreeCall 0500 321111
or visit www.evident.co.uk

Best regards

Stephen Selwyn BDS

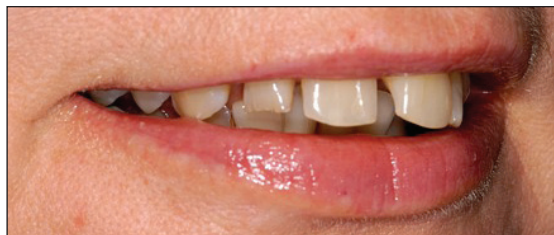

Evident
...it's all about quality

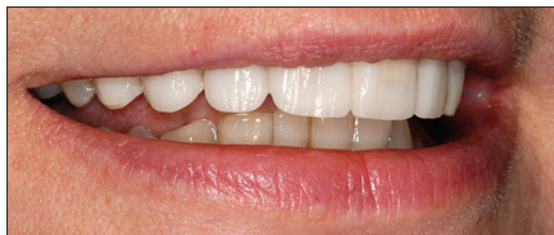FreeCall 0500 321111
www.evident.co.uk

Case two

Transitional restorations testing space closure and change in bucco-lingual inclination of anterior teeth.



Pre-operative smile of proclined and discoloured teeth with multiple diastema

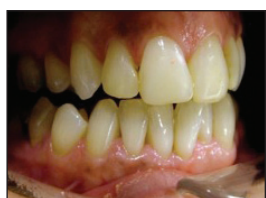

Transitional Luxatemp restorations after artistic contouring

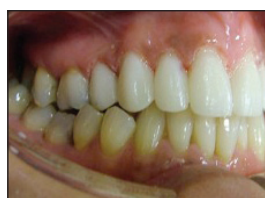It is within this framework that the entire smile is developed. The best place to determine these variables is within the patient's mouth. The dentist's knowledge of smile design and the patient's guidance through functional movements and speech will dictate the final position and appearance of the incisors.

Case three

Transitional restorations showing change in perceived Golden Proportion and width/length ratio of teeth by changing the position of the reflective line angles.



Pre-operative retracted view of the teeth



Transitional Luxatemp restorations after artistic contouring

The information that needs to be forwarded to the ceramist should include:

- A copy of the above pre-treatment diagnosis, and possible corrections (e.g. estimated correction of centre line, gingival outline, tooth angulation and tooth shape and size)
- Full set of extra-oral and intra-oral photographs
- A preliminary set of upper and lower arch impressions using a polyvinyl siloxane material (to allow multiple, accurate pouring of impressions)
- Registration of the patient's occlusion in centric relation or centric occlusion (as appropriate) using a face bow transfer
- Incisal index
- Precise measuring of length and width of teeth using a Jeneric Pentron 'T' ruler
- The patient's specific wants and desires
- Phonetic observations.

The ceramist

After receiving the impressions, the ceramist will pour two sets of models using a high-quality die stone (Die-keen Ivory). The first set is used for diagnosis and will be untouched as a 'before' model.

The second set is the working model for carrying out trial preparations and then diagnostic wax-ups, to establish the position, size and shape of teeth in the ideal arch-form, with the correct anterior and canine guidance.

Once the diagnostic wax-up is completed and approved, a matrix can be fabricated with Sil-Tech putty. The matrix is used to fabricate the provisional restorations in the clinical session.

The technique

- After tooth preparation, the teeth are cleaned with Chlorhexadine Gluconate (Consepsis, Ultradent Products Inc) and rinsed with water
- All prepared teeth are spot etched in the middle third of the facial surface for 15-20 seconds and thereafter washed thoroughly
- Multiple layers of a desensitising agent such as Gluma is placed on the teeth, and gently air dried
- A thin layer of partially filled resin (e.g. Optibond 2FL) is placed on the teeth. A primer or single component bonding system should not be used as the temporaries will be difficult to remove
- Each tooth is cured for 20 seconds with an LED light or a conventional halogen light
- The matrix is then filled with Luxatemp, placing the syringe tip deep within the matrix to avoid air bubbles. The matrix is seated on the teeth, then removed after three minutes
- Any gross excess material is trimmed with a bur before recontouring, finishing and polishing
- LuxaFlow can also be used to repair or add on to the temporaries. These areas can be micro-etched or roughened with a bur and a bonding agent applied. However, our experience shows that these additional steps are not practically necessary
- Finishing burs are used to finalise the marginal aspects (being careful not to disturb the tissue or alter the final preparations)
- Time is taken to accurately adjust the provisional restorations for an 'ideal smile' and correct occlusal form
- The final lustre is created with Luxaglaze Glaze and Bond. This is painted onto the temporary restorations, air-dried and light-cured.

The artistic keys of adjusting provisional restorations

- Teeth must not be convex and bulbous
- Teeth should have a series of subtle concavities and convexities on the labial/buccal surfaces
- Alter the facial proximal line angles to create variance in teeth
- Central incisors should be symmetrical with a variance of no more than 0.2mm in any direction
- Central incisors are often the dominant teeth, they have three lobes
- Lateral incisors have tapered cervical necks and are often slightly tucked in behind the centrals. They have an S-shaped concavity on the distal side
- Canines should have two facial planes mesiodistally, where the distal half is not visible from the anterior view. The canine eminence is an important factor regarding lip support
- Premolars can be built out at the junction of the incisal third and middle third of the tooth, into the buccal corridor to reduce lateral negative space.

A functional and aesthetic preview to a new smile

Fabrication of the final restorations should begin only after the occlusion has been checked, the provisional restorations are accepted to be comfortable and stable and the patient is happy with the smile design. This typically requires the provisional to be in place for a few days in order to obtain family approval and suggestions as well as confirm phonetic control.

A visit is arranged for the patient to come and have a review of the trial smile.

Valuable feedback can be gained by asking the following questions:

- What do you like about your new provisional smile?
- What do you dislike about your provisional smile?
- What other changes would you like us to make for your definitive smile?
- Please give us a rating out of 10 on how pleased you are with the provisional smile.
- Are you happy with the shade? Would you like us to make the final shade the same, darker or lighter?
- Are you happy with the surface texture and smoothness?
- Do you prefer the right-hand side or the left-hand side of your new smile?
- Are you happy with the length of the front teeth?

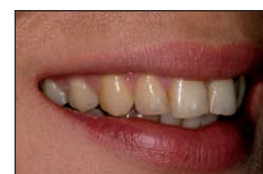These questions really allow the practitioner to understand the patient's aesthetic wants of their new smile. Further simple changes can be made to the provisionals as appropriate; after gaining these important viewpoints from the patient. This is done by further recontouring the Luxatemp and/or adding LuxaFlow in specific areas, so the patient can have another preview and confirm acceptance of the trial smile.

The following records are taken at this visit to communicate to the ceramist the approved form and shape of the provisional restorations including a confirmation of the patient's desire of the shade:

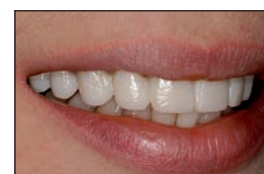- An accurate silicone impression of the temporaries
- Further digital photographs of the patient's smile
- Precise lengths of the six anterior teeth using a Jeneric Pentron 'T' ruler (with an accuracy of up to 0.1mm)
- A check bite record of the provisional restorations and the opposing arch using Luxabite (DMG) (if the occlusion is challenging)
- A stick bite of the transitional restorations.

The concept

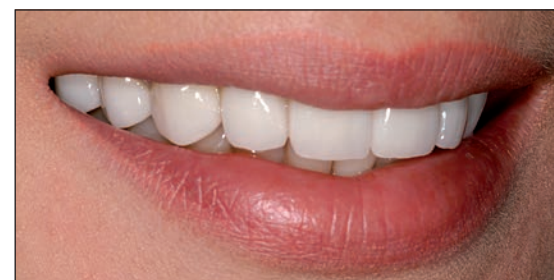The perfect smile through exceptional provisional restorations:



Pre operative view of the patients smile



Transitional Luxatemp restorations after artistic contouring



Post-operative view of the perfect smile

Conclusion

Temporisation is an integral part of comprehensive treatment involving smile design concepts. It represents the treatment phase that allows a dentist to be an artist. Temporary fabrication also provides proper communication for the laboratory, which directly affects the case. Eliminating as much of the guesswork as possible helps create a predictable result, and a happy smiling patient.



Pre-operative smile showing moderate anterior crowding



Creation of a life changing smile

Dr Rahul Doshi, from The Perfect Smile Studios and The Advanced Training Institute, will be lecturing at the BACD 2011 on minimal preparation restorations through perfect provisionalisation.

This will be a hands-on session to outline a simple system to achieve a predictable occlusal and aesthetic rehabilitation through beautiful provisional restorations.